

Case Presentations: Low-frequency Ultrasound Therapy for the Treatment of Painful and Difficult-to-Treat Leg Ulcers

Kazu Suzuki, DPM CWS, and Joel Aronowitz MD.

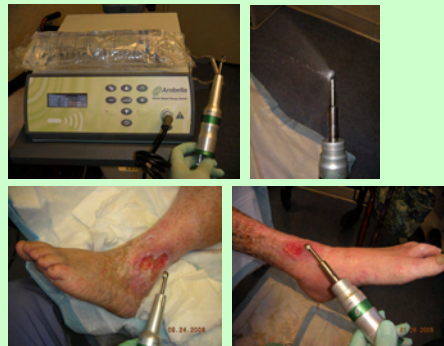Tower Wound Care Center, Cedars-Sinai Medical Towers, Los Angeles, CA.

Introduction:

Low-frequency ultrasound therapy (in the range of 30-100kHz) has been known to have various positive effects in tissue restoration and wound healing. The therapeutic effects of ultrasound on wounds are mainly two-fold:

- (1). Cavitation effect:** Fibrinolytic separation of denatured protein, resulting in selective debridement & defragmentation of non-viable tissue. Direct killing of surface bacteria and biofilms.
- (2). Stimulatory effect:** "Fluid shear stress" that generates nitric oxide within the endothelium for vasodilatation, resulting in increased blood flow. Stimulation of fibroblasts, macrophages and endothelial cells to augment healing.

The *Quostic wound therapy system* is the latest low-frequency ultrasound system (35kHz) that combines the sharp "curettling" debridement with continuous saline irrigation, while delivering focused therapeutic ultrasound to the wound bed.



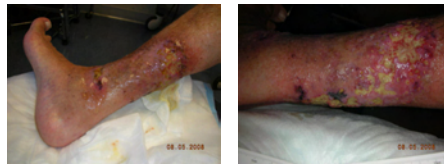Presentations:

We present the three lower-extremity wound patients successfully treated in our clinic using the low-frequency ultrasound device (*Quostic wound therapy system, Arobell Medical LLC*). These patients had unique wounds that were particularly painful to conventional sharp debridement, and had odd-shapes and sizes to make the conventional method of debridement particularly exhaustive and time-consuming.

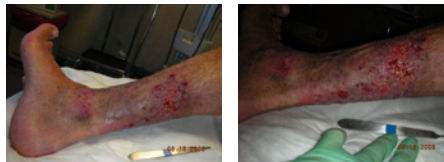This modality has been proven to increase the rate of wound healing in several randomized controlled studies (Ennis *et al*, OWM, 2005, Kavros *et al*, Adv in Skin & Wound 2007), while minimizing the pain inflicted on the patient, even when compared to other high-intensity ultrasound debridement devices. (Niezgoda JA, SAWC 2006).

Case 1.

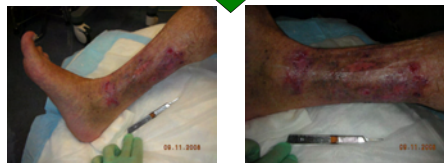61 yo male with rheumatoid arthritis. Recurrent pyoderma gangrenosum of the lower leg.



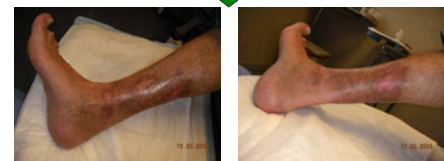Initial Presentation: Exquisitely painful, odd-shaped skin lesion. Managed with high-dose prednisone and moist dressing, with no improvement. Ultrasound wound therapy with the Quostic device started.



Clinically much improved with less pain and less edema. Skin lesions are smaller and shallower. No sign of *pathergy* (aggravation of the inflammatory disease) often seen in PG. Weekly office visit with foam dressing with mild compression continued.



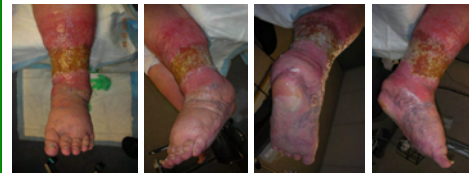Further improvement noted. Increased epithelialization. Minimal pain per patient. Instructed to taper off prednisone.



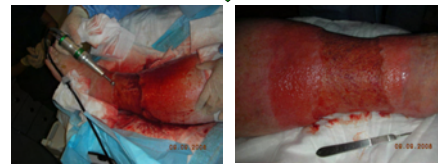Complete wound closure achieved. "No pain" per patient. Prednisone tapered back to the low maintenance dose.

Case 2.

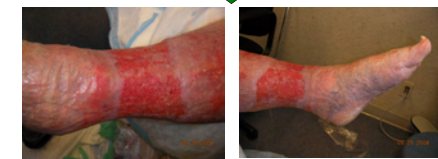60 yo female with acquired lymphedema with chronic circumferential ulceration of the ankle.



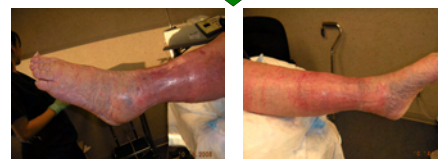Initial Presentation: Very painful, circumferential ulceration around the ankle. Too painful for compression treatment. Pain management consult obtained, prescribed Oxycodone extended release PO for pain control.



Taken to OR for IV sedation with popliteal/femoral block. Sharp debridement and irrigation done simultaneously with the Quostic ultrasound device. Foam dressing with compression bandage applied.



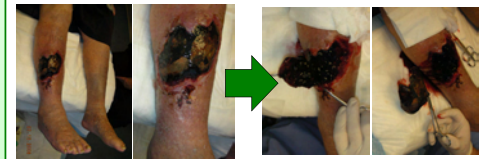
Twice weekly office visit with ultrasound therapy & dressing change. Further improvement noted. Increased epithelialization with minimal edema. Pain has subsided, managed with hydrocodone/APAP PO as needed.



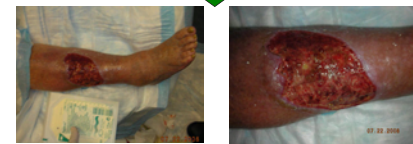Complete wound closure achieved. Fitted for compression hose. "No pain at all" per patient. Pain medications tapered & discontinued.

Case 3.

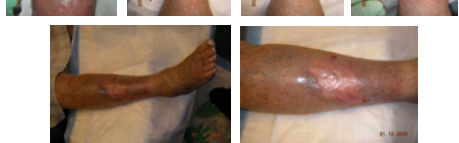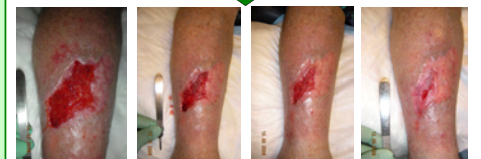
87 yo female with large leg hematoma and open wound, sustained from operating room restraint strap.



Initial Presentation: Eschar sharply excised. Hematoma evacuated, and the wound base debrided/irrigated with the Quostic device.



Follow-up visit: Clinically much improved with less pain. Granulation tissue formation and the contraction of the wound size noted. Continue weekly ultrasound treatment, foam dressing + compression bandage.



Treatment course was prolonged due to her cardiac and other medical issues. The wound eventually healed. No pain from the wound reported by the patient. Fitted for compression hose at this time.